

An Overview of Ultrasound Testing For Lesion Detection in Human Kidney

Aina Fadhilah Abd Rahim¹, Zawin Najah Abd Halim¹, Jaysuman Pusppanathan^{1*}, Muhammad Haikal Satria¹, Fatin Aliah Phang¹, Mohd Najeb Jamaludin¹, Amir Putra Bin Md Saad^{2,3}

¹Faculty of Bioscience and Medical Engineering, Universiti Teknologi Malaysia, 81310 Skudai, Johor, Malaysia

²Department of Applied Mechanics and Design, Faculty of Mechanical Engineering, Universiti Teknologi Malaysia, 81310 Skudai, Johor, Malaysia

³Sports Innovation and Technology Centre (SITC), Institute of Human Centred and Engineering (IHCE), Universiti Teknologi Malaysia, 81310 UTM Skudai Johor, Malaysia

1. Abstract

Ultrasound waves are commonly used to produce images of the human internal organs such as kidney. Most kidney cancers are found unexpectedly when patient have an ultrasound or scan for symptoms that turn out to be unrelated. Usually, the first test a medical doctor will do is an ultrasound scan, which is a real-time, moving test used to detect and differentiate between tumours, stones and cysts on the kidney. This paper presents the overview of ultrasound imaging for renal screening to detect renal lesions such as tumor, stone and cyst.

Keywords: Renal screening, kidney lesion, ultrasound imaging.

2. Introduction

Ultrasound imaging has been widely used in the medical field to view the internal structure of the human body so that the diagnosis, monitoring and treatment processes can be done. Ultrasound for imaging basically applies the concept of transmission and reflection of the waves. This technique can be performed by using a transducer that could transmit the ultrasound waves into the body by placing the transducer non-invasively on the skin surface. Although there are many other imaging modalities available for the medical purposes such as X-Ray and Magnetic Resonance Imaging (MRI), ultrasound technique is more favorable as it does not emit any ionizing radiation that could harm the patient and user [1]

3. Background Study

Ultrasound wave also has its own limitation in transmission. The main factor that would affect the ultrasound transmission is the acoustic impedance of the transmission medium. The value for acoustic impedance can be obtained by multiplying the density of the organ

with the velocity of the ultrasonic wave. The medium that cannot be transmitted by the ultrasound wave would return all the wave back to the transducer and this would result in a dark spot on the ultrasound image.

The diagnosis of the kidney related disease can be done by the ultrasonography imaging [2]. The kidney is one of the important organs of the excretory system in the human body as it functions to filter the blood in order to remove the wastes and extra water. The anatomy of the human kidney can easily visualize by using the B-mode ultrasound imaging [2]. A lesion is the abnormal growth of any tissue or organ due to any disease or injury. The lesion has many types such as the cyst, tumor, kidney stone and many more. This lesion can visualize and distinguish by the ultrasound imaging and this is the common procedure in the clinics in order to view the lesion inside the kidney.

4. Ultrasound Imaging in Medical Field

In medical ultrasound imaging system, the transducer act as a capacitive device. Inside the transducer, there is a phased array of the piezoelectric crystal that plays the major role in energy conversion. The transducer will change the electrical voltage supplied by the system to the ultrasound signals and also can receive back the echo signals and convert it into voltage measurement [3]. The basic components of the ultrasound transducer are the backing layer, piezoelectric layer and impedance matching layer (figure 1) [1]. The presence of backing layer is to ensure that the piezoelectric element would not generate any vibration that is beyond the limit. A high vibration would produce a higher ultrasonic pulse length that could cause a poor resolution for the image Piezoelectric layer is made up of either from natural crystals such as quartz or manufactured compound like zirconate titanate [1]. These crystals would generate the ultrasonic waves and also can generate the voltage. The matching layer function is to ease the transmission of ultrasonic waves from the transducer into the body by covering the high difference in acoustic impedance between the piezoelectric element and the soft tissues.

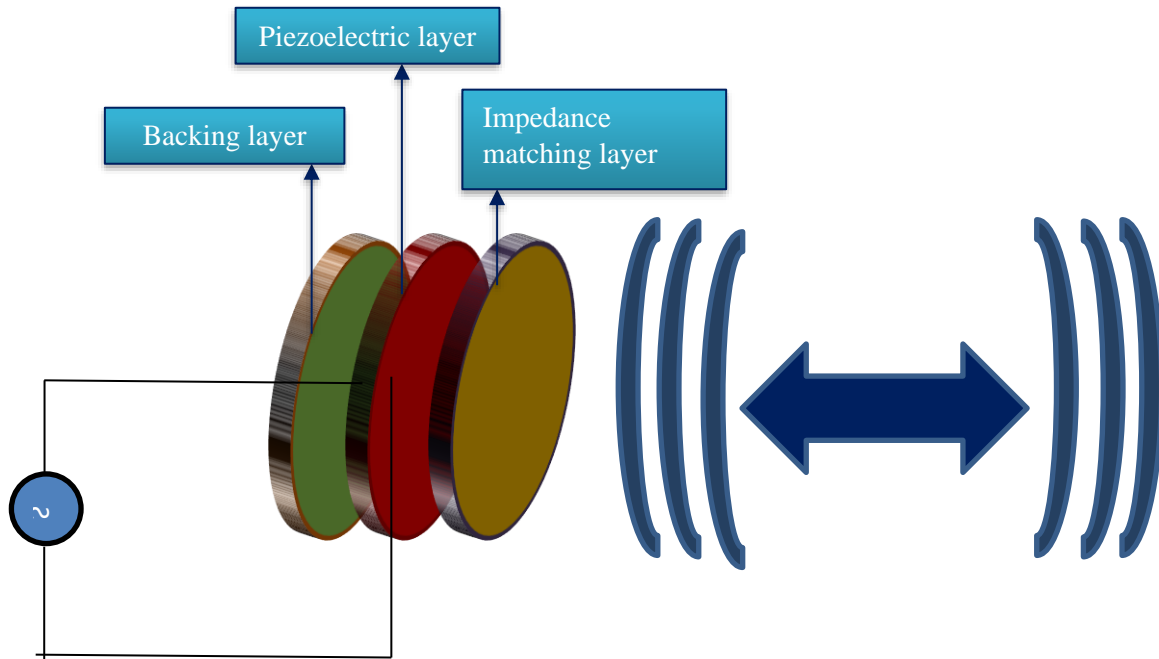


Figure 1 Working Principle Pulse Echo Modes

The brightness of the image displayed depends on the amount of energy that reflected back. To get a high returned energy, the acoustic impedance difference between ultrasound wave and the medium must be large. As for the 2-dimensional ultrasound image, the parameter that must be calculated is the depth of the tissue interface (d) by using the information of the ultrasound average speed (c) and also the time taken for the ultrasound wave to bounced back and return to the transducer (t). Equation (1) used to calculate the depth of tissue interface is shown as follows [4]:

$$d = \frac{ct}{2} \quad (1)$$

5. Lesion in the human kidney.

A lesion is the abnormal tissue growth or any form of growth that can happen in the human kidney. Some of the lesion can cause certain diseases while the others can just be a scar. The lesion can be malignant which is cancerous or benign which is non-cancerous. Although benign lesion is non-cancerous, without a good care and protection, these benign type of lesion can become cancerous. There are many types of lesion that present in kidney with the size less than 3 mm in length.

The kidney stone is made up of crystalline structure and it can be detected easily by using the ultrasound. By using the B-mode ultrasonography, the ultrasound image of a kidney stone would be bright and sometimes can have a dark distal shadow. The kidney stone is appeared bright due to the facts that it will strongly reflect the ultrasonic waves thus the wave was unable to penetrate through [5]. The image for ultrasound imaging of a kidney with stone is shown in figure 2 follows.

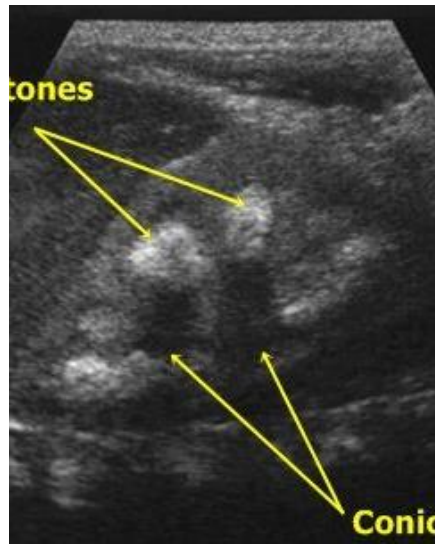

Figure 2 Kidney stone image using ultrasound

Cysts is a sac-like structure that contains liquid, gases or any other semisolid substance [6]. Air and gas state substances have a property that would reflect all the ultrasound wave and thus restrict the propagation of the wave through the medium [6]. Cysts can present in any tissue or organ and the factors that cause the cyst development are the infections, tumors, chronic inflammatory conditions and also some inherited diseases. Normal cysts didn't cause any harms but to ensure whether the cyst is safe, an ultrasound scanning need to be done. The frequency needed for the ultrasound transmission in order to make it able to distinguish between a cyst or any solid lesion is by using a B mode imaging techniques with a high spatial and contrast resolution [7]. Theoretically, a cyst structure would appear dark in the ultrasound image as it contained some gases. Usually, the size of cyst inside a kidney is around 5 to 10 mm in diameter [8]. The ultrasound figure of a cyst with kidney is shown in Figure 3 as follows.

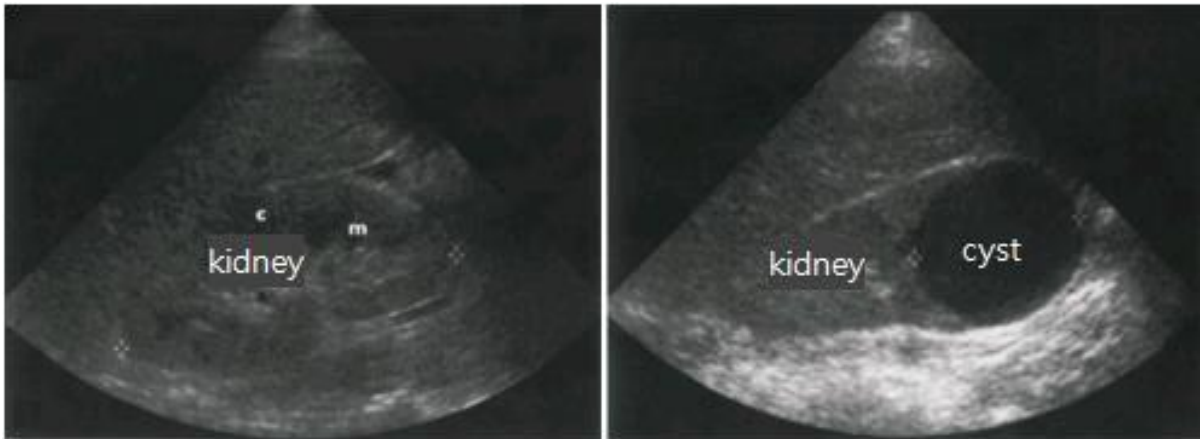


Figure 3 Kidney cyst image using ultrasound

A tumor is an abnormal growth of the cells. It is a kind of lump or swelling and does not pose health treat. The structure of a tumor may be solid or fluid-filled sac of structure. The structure of the tumor is completely different from the cyst as it is a solid mass with internal echo and don't have a well defines walls. The tumor can either be malignant or benign. For a malignant tumor, it usually arises from the urothelium and the example for the malignant tumor is the lymphoma, adenocarcinoma and metastases. One of the examples of the benign tumor are the angiomyofibroma which are composed of fat, smooth muscle tissue and vascular element. This tumor lesion is usually hyperechoic [2, 9]. Figure 4 shows the ultrasound image of kidney with the tumor. The sound speed of a tumor is in the range of 1611 to 1616 m/s at frequency of 1 to 3 MHz [10].

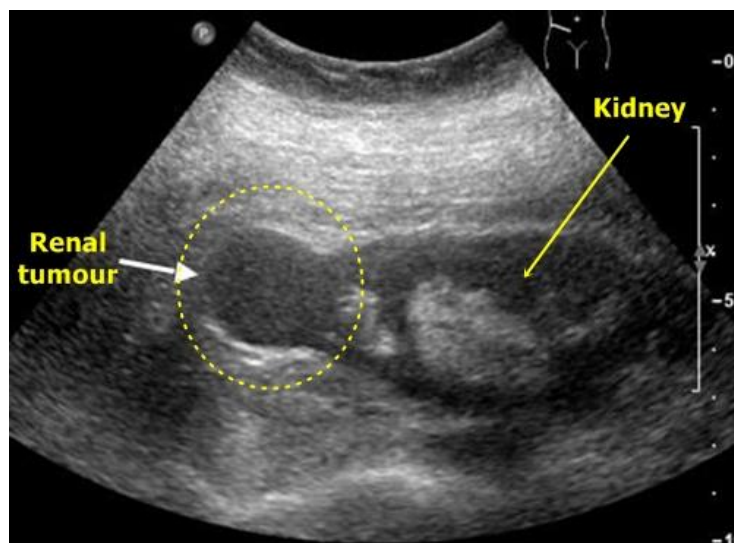


Figure 4 Renal Tumor image using ultrasound

6. Conclusion

This paper has presented a brief overview of ultrasound testing for lesion detection in human kidney. Ultrasound technique for imaging is much preferable due to its non-ionizing and non-radiative method for renal screening. The most common application for the usage of this method is to detect lesions in kidney such as kidney tumor, cyst and stone. Such lesion could be categorized as malignant or benign type where each lesion will have different measurable parameters to be detected.

Acknowledgment

This research study is carried out with the support from University Research Grant (GUP) 02K97 and 4C166 under Universiti Teknologi Malaysia.

References

- [1] Raj, B., V. Rajendran, and P. Palanichamy, *Science and technology of Ultrasonics* 2004: Alpha Science International Ltd 371.
- [2] Hansen, K.L., M.B. Nielsen, and C. Ewertsen, *Ultrasonography of the Kidney: A Pictorial Review*. *Diagnostics*, 2016. **6**(1): p. 2.
- [3] Moon, J.-Y., J. Lee, and J.H. Chang, *Electrical impedance matching networks based on filter structures for high frequency ultrasound transducers*. *Sensors and Actuators A: Physical*, 2016. **251**(Supplement C): p. 225-233.
- [4] Martin, D.J., I.T.P. Wells, and C.R. Goodwin, *Physics of ultrasound*. *Anaesthesia & Intensive Care Medicine*, 2015. **16**(3): p. 132-135.
- [5] Brisbane, W., M.R. Bailey, and M.D. Sorensen, *An overview of kidney stone imaging techniques*. *Nature reviews. Urology*, 2016. **13**(11): p. 654-662.
- [6] Nordqvist, C. *Cysts : Cause, types and treatments*. 2017 16 August 2017 [cited 2017 27 October 2017]; Available from: <https://www.medicalnewstoday.com/articles/160821.php>.
- [7] Iuanow, E., et al., *Accuracy of Cyst Versus Solid Diagnosis in the Breast Using Quantitative Transmission (QT) Ultrasound*. *Academic Radiology*, 2017. **24**(9): p. 1148-1153.
- [8] Simms, R.J. and A.C.M. Ong, *How simple are 'simple renal cysts'?* *Nephrology Dialysis Transplantation*, 2014. **29**(Suppl 4): p. iv106-iv112.
- [9] Zwingenberger, A. *What do hyperechoic and hypoechoic mean?* 2009 24 August 2009 24 December 2017]; Available from: <http://www.veterinaryradiology.net/4161/what-do-hyperechoic-and-hypoechoic-mean/>.
- [10] Keshavarzi, A., et al., *Attenuation coefficient and sound speed in human myometrium and uterine fibroid tumors*. *Journal of Ultrasound in Medicine*, 2001. **20**(5): p. 473-480.